

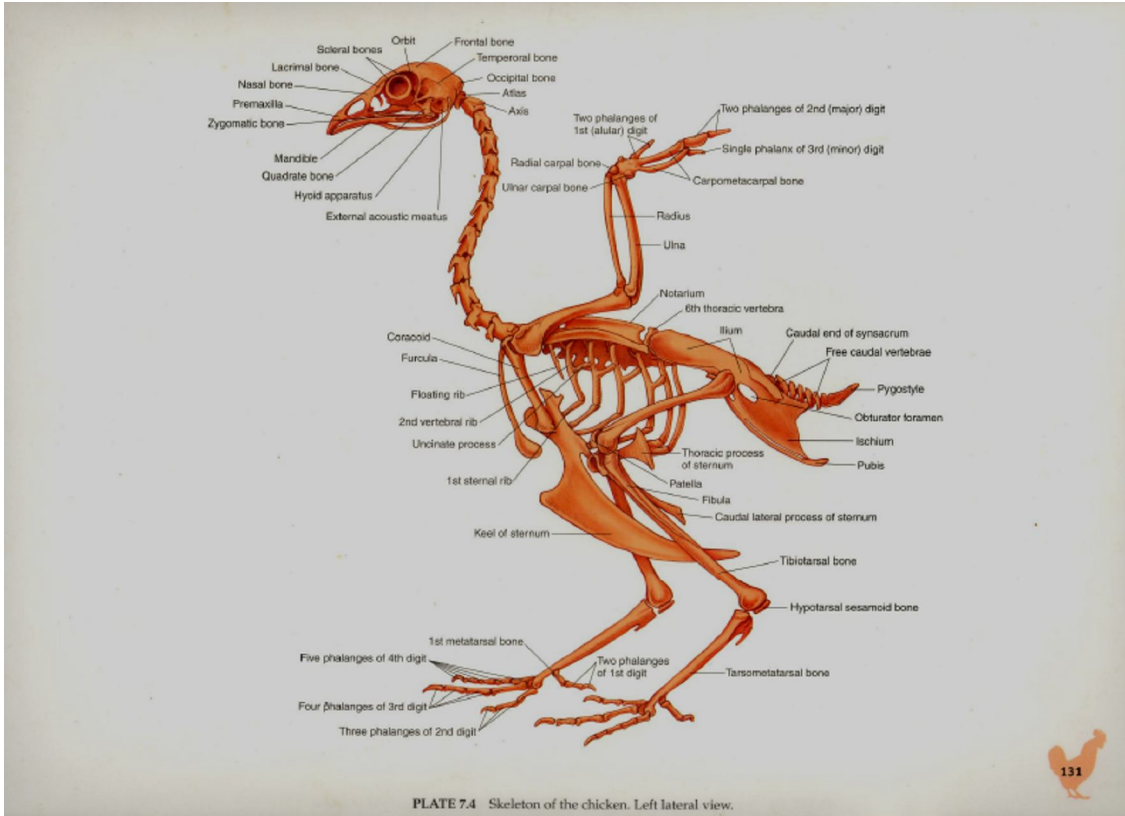PLATE 7.4 Skeleton of the chicken. Left lateral view.

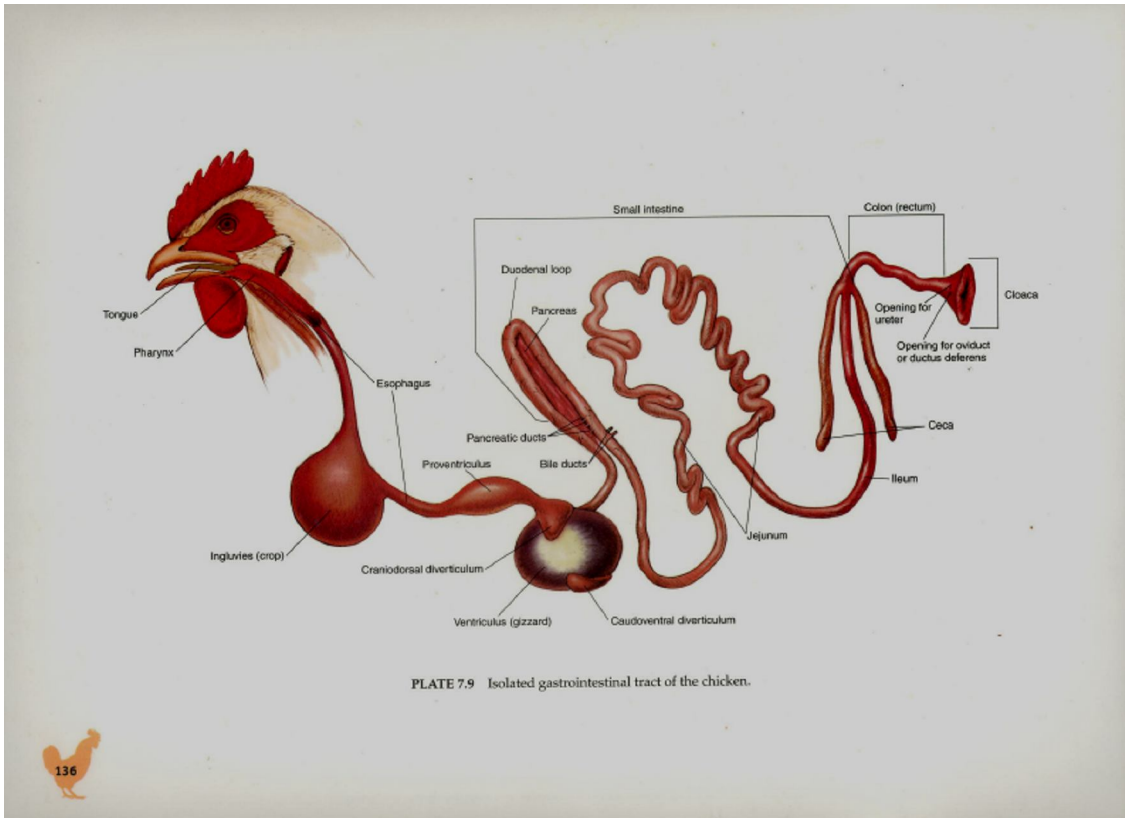


PLATE 7.9 Isolated gastrointestinal tract of the chicken.